



CONDITION

What is a Thumb Ulnar Collateral Ligament injury?

(Skiers thumb or Gamekeepers thumb)

This is an injury to the strap ligament on the inside of the thumb. It can result in an unstable thumb that gives way when used if not treated appropriately

What are ligaments?

Ligaments connect bones to bones across joints. When the joint moves the ligaments help keep the joint lined up and stop it dislocating.

What ligaments are there in the hand?

There are many ligaments in the hand but the most important ones limit sideways movement of the joints. Of these so called 'collateral ligaments' the one on the inner side of the thumb is most commonly injured, the ulnar collateral ligament.

How can this ligament be injured?

Falling onto the thumb and bending it out sideways can tear this ligament. A common way to do this is to fall whilst holding a ski pole. In years gone by gamekeepers stretched out this ligament using their thumb to snap the necks of rabbits they had caught, hence the other name for the injury.

How do we know if this ligament has been injured?

A fresh injury in this area is painful, swollen and bruised. Later on just the instability of the joint may be all that remains.

Are other investigations required?

Xrays are useful to look for associated fractures.

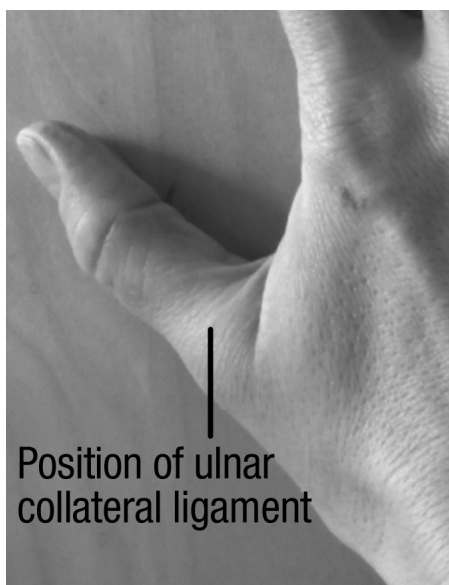
What is the treatment for this injury?

Minor stretches of the ligament may heal by themselves. A supportive splint, ice, pain killers and some gentle exercises to regain thumb mobility after a week or two may help.

If the ligament is completely torn the end can flip around the overlying strap and will not repair properly. This is called a 'Stener' lesion after the person who first described it. Left like this the joint remains unstable and difficult to use. In this situation the ligament should be surgically repaired.

What function can I expect after this injury?

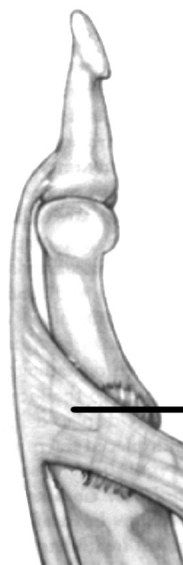Incomplete injuries and torn ligaments repaired early usually do well with appropriate rehabilitation. Occasionally the repair fails or the diagnosis is missed initially. Other treatments might then be necessary and the results will be less certain. Your specialist can advise you regarding your particular injury.



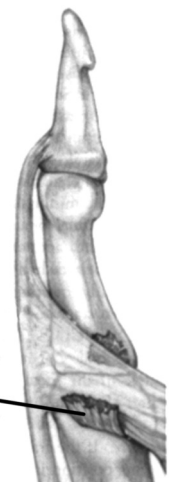Position of ulnar collateral ligament

Thumb ulnar collateral ligament position

(sits below another strap, seen in diagram)



Adductor aponeurosis over the top of the ulnar collateral ligament



Torn ulnar collateral ligament caught on the edge of the adductor aponeurosis after injury

The 'Stener' lesion