

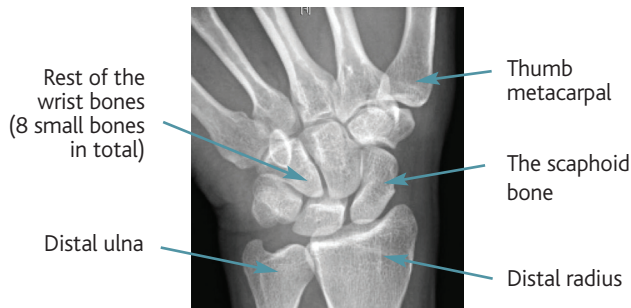

CONDITION

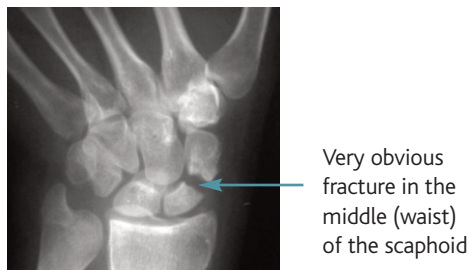
What is a Scaphoid Fracture?

The scaphoid is one of the small bones that make up your wrist. It is the commonest wrist bone to break.

Normal Wrist Xray



A fracture of the scaphoid



Sometimes the diagnosis is delayed, often by months or years. In this situation xrays, MRI and CT scans might all be required to make a full assessment of what is needed.

Sometimes an operation is recommended. The exact approach will depend on the type of injury. Commonly a screw is placed down the centre of the scaphoid to keep the fragments lined up and still whilst the bone heals. This can sometimes be done in a minimally invasive way with very small incisions (see 'Percutaneous screw fixation of Scaphoid Fractures'). Later on bigger operations might be necessary to re-align a bent scaphoid and put new bone into the old fracture (see 'ORIF of Scaphoid Fractures +/-bone grafting').

What treatment is needed for a scaphoid fracture?

This depends on a great many things. Some important factors are:

- 1. How old is the injury?** Fresh fractures have better healing potential
- 2. Which part of the scaphoid is broken?** The nearer the fracture is to end of the scaphoid next to the radius (proximal pole) the more chance there is of problems with healing. This is to do with the blood supply to the scaphoid bone which is not good in the proximal pole.
- 3. How badly out of position is the scaphoid in relation to the surrounding bones?** The scaphoid is rather 'banana shaped' normally. If it breaks it tends to become more bent in the middle. In that case it does not line up with the other bones in the wrist so well and this can lead to arthritis in the wrist later on (see page on 'SLAC and SNAC wrist').
- 4. Do you smoke?** This increases the chance of the scaphoid not healing up. This probably relates to the blood supply to the bone which is reduced by smoking.
- 5. What other structures are damaged?** These might also need treating.

What is the outcome following a scaphoid fracture?

This mainly depends on whether or not the scaphoid heals, how normal the shape of the scaphoid is after healing and how stiff the soft tissues get during treatment. Associated injuries can also affect the outcome. Even patients with an apparently perfectly healed scaphoid fracture treated just in a cast describe the occasional twinge in their wrist after this bone has been broken.

How do scaphoid fractures occur?

The commonest way to break this bone is simply to trip and fall landing heavily on the palm of your hand. The other way of breaking the scaphoid is by punching something. The fracture is common in young adults between 17 and 30 but can occur as early as 11 and as late as into your 80s.

How is the diagnosis made?

This can be surprisingly difficult. It is important to get a clear history from you, the patient, and examine the wrist very carefully. Often the fracture is obvious on a simple Xray. If no fracture is seen on the original Xray but significant pain persists 10-14 days after the injury a scan can be helpful to confirm the diagnosis. A magnetic resonance imaging (MRI) scan is most sensitive at picking up these injuries and this will also show up any other significant soft tissue injuries that might have occurred.