

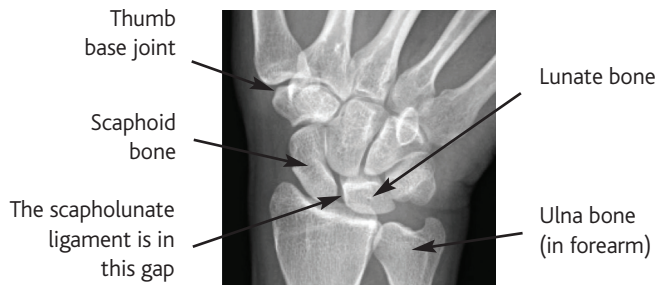


CONDITION

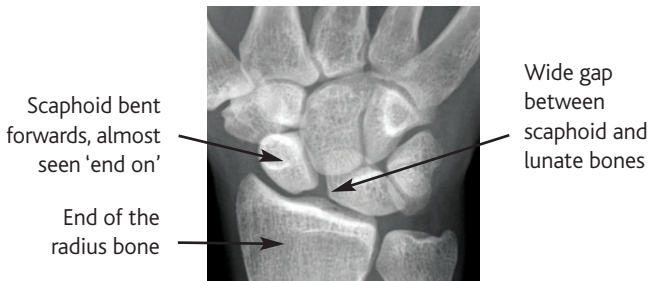
What are Scapholunate ligament injuries?

The scapholunate ligament links two small bones in the wrist together. It is the most commonly injured ligament in the wrist. Complete rupture of this ligament eventually leads to arthritis in the wrist.

Normal Wrist Xray



A Wrist Xray showing a ruptured Scapholunate Ligament



Why is the scapholunate ligament important?

The scapholunate ligament links the scaphoid and lunate and forces the two bones to move together in a co-ordinated way. Once the link is broken the two bones don't sit properly and start to clunk and click. This wears the joint out and eventually, over about 5-10 years, a pattern of arthritis called scapholunate advanced collapse (see 'SLAC and SNAC wrist') occurs.

What causes a Scapholunate ligament injury?

The usual cause is a fall onto the outstretched hand. Some inflammatory conditions, such as gout, can also weaken the scapholunate ligament.

What symptoms does a Scapholunate ligament injury produce?

Symptoms from a scapholunate ligament injury are very variable. Patients often describe pain in the wrist sometimes with swelling in the centre of the back of the wrist. Clicking and clunking with use may be noted. The wrist will usually be stiffer than the other side (less flexible). Once arthritis sets in the swelling and stiffness can become more marked.

How is the diagnosis of a Scapholunate ligament injury made?

The story of your symptoms and a careful examination usually suggest the diagnosis. It is common for no specific injury to be recalled.

The obvious changes shown in the pictures are unfortunately the exception rather than the rule and Xrays will often be normal in the early stages of this condition.

A magnetic resonance imaging (MRI) scan with dye injected into the joint (an arthrogram) is the most sensitive test for confirming the diagnosis. Dye should not leak between the scaphoid and lunate bones during this test.

If a significant ligament injury is suspected a wrist arthroscopy (looking into the wrist with a telescope) could be the next step. During this operation the wrist joint and the scapholunate ligament can be directly inspected.

What treatments are available for a scapholunate ligament injury?

The treatment recommended depends on how damaged the ligament is and whether there are any signs of arthritis in the joint.

Slight stretching of the ligament can often be managed with a combination of painkillers, splints and activity modification. Focussed hand therapy can be useful to strengthen muscles that support the movement of the wrist and scaphoid.

If the ligament is more damaged surgery to reconstruct the ligament might be indicated. Various options are available.

If the ligament is completely ruptured and the diagnosis is made early (ideally less than 6 weeks after the injury) a repair of the ligament might be successful.

If the diagnosis is made very late, after arthritis has started, treatments aim to relieve symptoms (see 'SLAC & SNAC wrist').

If gout or pseudogout is suspected medical treatment with drugs can be very useful and this may need to be discussed with your GP or a Rheumatology Consultant.

What is the outcome after a scapholunate ligament injury?

Again this depends on the degree of damage the ligament has suffered and the type of treatment undertaken.

The type of operations mentioned above do seem reasonably reliable at improving stability of the scaphoid and reducing symptoms, at least in the short to medium term. They will all make the wrist somewhat stiff to a greater or lesser extent. In the longer term there is some evidence that the ligament reconstruction operations may stretch out with time, with some recurrence of symptoms.

We do not have the perfect solution to this problem at the moment and more work is underway to consider fresh ways to address scapholunate ligament injuries.