

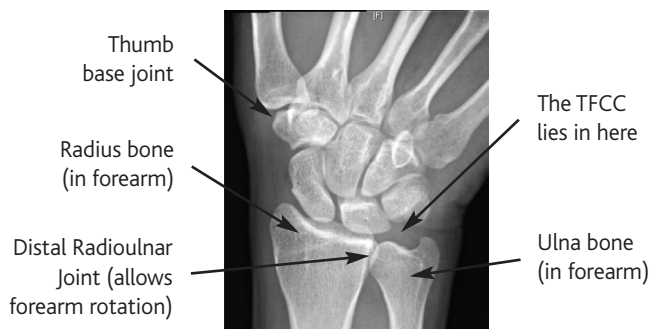


CONDITION

What are TFCC Injuries?

Damage or injury to the TFCC can produce pain on the ulnar (little finger) side of the wrist.

Normal Wrist Xray



What is the TFCC?

TFCC stands for Triangular Fibro-Cartilaginous Complex. It is the name given for the various soft tissue structures that lie between the end of the ulna and the rest of the wrist bones (see picture).

What can go wrong with the TFCC?

The TFCC can wear out with age, in a rather similar way to the 'shock absorbers' in the knee (menisci) wearing out.

The TFCC can also be torn. In the middle the TFCC is rather thin with a poor blood supply and tears there will not heal. Around the edges the complex is thicker with a better blood supply and has more ability to heal if the damaged ends are held together.

What symptoms does a damaged TFCC produce?

If the TFCC is slightly torn or worn out in the middle there may be pain on the ulnar side of the wrist, particularly when the wrist is loaded and rotated at the same time, for instance when using a screwdriver.

If there is a big tear in the edge of the TFCC as well as discomfort you may feel that the wrist is clunking or unstable. This tends to happen with rotation and occurs as the stabilising influence of the TFCC on the distal radioulnar joint is reduced.

If the wear and tear process continues arthritis type symptoms may occur (see 'Ulnar abutment' and 'Distal Radio Ulnar Joint Arthritis')

How is the diagnosis of a TFCC injury made?

The story from you about your symptoms and a careful examination usually suggest the diagnosis. There may or may not be a specific injury that you can recall.

An Xray will usually be ordered to check how long the radius and ulna are with respect to each other and to look for arthritis. Early on this will often be normal.

A magnetic resonance imaging (MRI) scan with dye injected into the joint (arthrogram) is the most sensitive test to look for a tear in the TFCC.

If there are problems with the DRUJ a computerised tomography (CT) scan is occasionally useful to compare that joint to the one on the other side with the wrist in various degrees of rotation.

If a significant injury is suspected on these tests and the symptoms remain an issue a wrist arthroscopy could be the next step. During this operation the wrist joint and the TFCC are directly inspected through a small telescope.

What treatments are available for a TFCC injury?

The treatment recommended depends on where the damage is, how extensive the damage is and whether there are any sign of arthritis in the joint. Tears in the middle of the TFCC or early wear and tear can often be trimmed up through the arthroscope.

Tears around the edge of the TFCC are often repaired, particularly if the DRUJ is unstable. Sometimes this can be done through the arthroscope but more usually this requires a small open operation.

Once arthritis has set in treatment aims to reduce those symptoms (see 'Ulnar Abutment' and 'Distal Radio Ulnar Joint Arthritis').

What is the outcome after a TFCC injury?

This depends on the degree of damage the complex has suffered and the type of treatment undertaken. Studies suggest it is difficult to completely relieve all symptoms following damage to the TFCC, even with what appears to be a successful repair of the complex. Significant improvements in pain and function can be expected however in the majority of patients. Our understanding of this part of the body continues to evolve, along with our understanding of which surgical procedures give the best outcomes for each patient.